

4  
C A S E S

OF

BRANCHIAL FISTULÆ IN THE  
EXTERNAL EARS.

BY

SIR JAMES PAGET, BART., D.C.L., LL.D., F.R.S.

Read November 27th, 1877.


[From Volume LXI of the 'Medico-Chirurgical Transactions,' published  
by the Royal Medical and Chirurgical Society of London.]

L O N D O N :

PRINTED BY

J. E. ADLARD, BARTHOLOMEW CLOSE

1878.



Digitized by the Internet Archive  
in 2015

<https://archive.org/details/b22303212>

CASES  
OF  
BRANCHIAL FISTULÆ IN THE  
EXTERNAL EARS.

BY

SIR JAMES PAGET, BART., D.C.L., LL.D., F.R.S.,

---

Received November 13th—Read November 27th, 1877.

---

BRANCHIAL fistulæ in the neck have been often and fully described in Germany, but have been so rarely noticed in this country that some short account of them may be useful for the better understanding of the rarer branchial fistulæ in the ears which it is my chief purpose to describe. They were first observed by Dzondi in 1829, and he gave them the name of Congenital Fistulæ of the Trachea, in the most probably erroneous belief that they opened into that canal.<sup>1</sup>

Ascherson, in 1832, besides adding many cases to those by

<sup>1</sup> See Heusinger, 'Virchow's Archiv für Pathol. Anat.,' xxix, p. 365, for explanation of Dzondi's probable mistake. No communication with the trachea has been suspected in any cases since Dzondi's, but three or four cases are recorded of congenital tracheal fistulæ in the middle line of the neck. These were certainly not branchial fistulæ; they may have been due to abscess opening into the trachea and through the skin, or may have been due in part to defective median closure of the branchial arches, after the manner of the malformation in ectopia cordis or ectopia vesicæ. See Fischer in v. Pitha u. Billroth's 'Handbuch,' B. iii, Ab. 1, L. 3, S. 41.

Dzondi observed the communication of some of the fistulæ with the cavity of the pharynx, and explained them as due to incomplete closure of the branchial clefts or fissures of the early fetal state. Several more recent writers, especially Heusinger,<sup>1</sup> have confirmed and extended Ascherson's descriptions and their interpretation; and I have found them true in three instances observed in the last three years.

In general terms, the cervical branchial fistulæ appear congenitally as very fine canals opening into minute orifices in one or both sides of the fore part of the neck, and leading backwards and inwards, or backwards and upwards, towards the pharynx or œsophagus. In some instances a single fistula is found; in others two; in a few three. In the greater number the orifices are just above the sterno-clavicular articulation; in others they are near the level of the upper border of the thyroid cartilage at the anterior edge of the sterno-mastoid muscle. When two orifices are found they are usually placed symmetrically; when three, it is usual for two to be placed at the lower level and one at the upper. In length the fistulæ are various, from half an inch to two and a half. In diameter they vary from that of an ordinary bristle to that of an ordinary probe, the orifices being usually smaller than the canals and less easy to dilate. At their distal ends the fistulæ are most frequently closed, after the manner of blind or incomplete fistulæ; in only a few instances they have been found complete, opening into the pharynx or the upper part of the œsophagus, but by apertures so narrow as only to admit minute probes, or the forcible injection of fluid. The lining of the fistulæ is a smooth, shining membrane, commonly secreting a clear mucous fluid; and, in one of the cases which I have seen,

<sup>1</sup> Loc. cit., and in the same 'Archiv,' B. xxxii. Translations of the papers of Dzondi and Ascherson are published in Clay's 'British Record of Obstetric Medicine,' vol. i, 1848. Heusinger gives references to about forty cases published before 1866; and references to later cases are given by Fischer, loc. cit., and by K. F. v. Heusinger in the 'Deutsche Zeitschrift für Thiermedizin,' B. ii (as quoted in 'Virchow and Hirsch's Jahresbericht' für 1867, p. 227), gives a complete account of all forms of cervical branchial fistulæ in domestic animals as well as in man.

this secretion was always augmented during any accidental bronchial or nasal catarrh. Very rarely portions of cartilage, such as may be thought arrested rudiments of cervical ribs, have been felt under the skin near the openings of the fistulæ.<sup>1</sup>

The cervical branchial fistulæ appear, as a rule, to undergo no material change from birth to the end of life. They may become so troublesome by their secretion as to need surgical treatment; and I believe that the best treatment is with the galvanic cautery applied through their whole length.

Such are, generally, the cervical branchial fistulæ, and it may suffice if I merely refer to the probability that some rare instances of diverticula from the pharynx may be regarded as dilatations of portions of branchial fistulæ closed externally but remaining open within; and to the further probability that some congenital and infantile cysts, and even some ranulæ, may be derived from branchial canals closed at both ends and distended with fluid, as hydrocele in the inguinal canal may be formed by the filling of part of a *canalis vaginalis*.<sup>2</sup>

Of the branchial fistulæ in the external ears no account, I believe, has yet appeared in this country, and in foreign literature I have found descriptions of only six or seven cases, and some of those are very incomplete.<sup>3</sup>

The instances of which I have to tell are in the family of a member of our profession, an active well-formed man. He showed me a well-marked branchial fistula on the left side of his neck opening near the middle of the anterior border of the sterno-mastoid muscle, and often yielding a thin, clear, mucous fluid. His father, he told me, had an exactly similar fistula, and so had one of his sisters. Moreover, of his eight

<sup>1</sup> Heusinger, *u. supra*, and in *B. xxxiii*, p. 177.

<sup>2</sup> These matters may be studied in Heusinger. 'Virchow's Archiv,' *B. xxxiii*, p. 177; Roser, 'Elémens de Pathologie Chirurgicale,' traduit par Culmann, 1870, p. 177; Schede, as quoted by Schmitz, *u. infra*; and K. F. v. Heusinger, in the 'Deutsche Zeitschrift,' *u. supra*.

<sup>3</sup> They are collected by Schmitz; 'Ueber Fistula Auris congenita: Inaug. Diss.,' Halle, 1873. The first and best case is by Heusinger, Virchow's 'Archiv,' *B. xxix*.

children four have, or had (for three of them are dead) similar fistulæ, secreting a "pure lymph," two of them having each one on the left side of the neck, and two of them each two on opposite sides symmetrically placed.

The prevalence of cervical branchial fistulæ in several members of a family, which has often been observed, is, in this instance, very marked; but that which is of more interest is that in this gentleman, and in his sister, and in five of his children, there are (or were) similar sinuses in the upper and anterior part of the helix of one or both ears.<sup>1</sup> Those which he showed me in himself, and which might be taken as examples, might easily be overlooked, for the orifice of each is minute, and the canal or fistula only just visible beneath the skin. The canal is little more than half an inch in length, and runs from behind forwards and a little downwards. It is less soft and flexible than the cervical fistulæ, and no secretion has ever been noticed; but he has observed that "on rubbing the part with pressure a peculiar waxy smell is communicated to the finger."

It might have been very hard to explain these fistulæ in the ears if their meaning had not been indicated by the co-existence of well-marked branchial fistulæ in the necks of the same persons or of members of the same family. Similar coincidence was observed in a case by Heusinger,<sup>2</sup> which I believe to have been the first recorded; and as the cervical fistulæ have been certainly proved to be the result of incomplete closure of the lower branchial fissures, so may these aural fistulæ be regarded as similarly due to incomplete closure of the upper or first post-oral fissure; or rather, of that part of it which is not utilised in the formation of the Eustachian tube, tympanum, and meatus.

So far as I know, these are the only cases in which the branchial fistulæ have been found opening on the helix.<sup>3</sup> In

<sup>1</sup> A child lately born to him, the offspring of a second marriage, has neither cervical nor aural fistulæ.

<sup>2</sup> Loc. cit., p. 361.

<sup>3</sup> Unless it be in a case, with malformed ears, related by Lineke, 'Handbuch der Ohrenheilkunde,' Leipzig, 1837, B. i, p. 615.

the other recorded instances the openings have been just in front of the lower and anterior part of the helix, or, in one doubtful case, in the lobule of the ear.<sup>1</sup>

I believe that nothing is known of the causes of these malformations or of the conditions leading to the failure of the process by which, normally, about the end of the second month of embryo-life, the branchial fissures are completely closed. And as to the placing of the unclosed part on the helix, we can only guess that when the auricle, as part of a cutaneous operculum, grows up from the posterior and upper part of the second post-oral branchial arch, it carries with it a part of the cleft between the second and first arches, and this fails to close and lengthens into a canal. But I venture to believe that we shall gain a most exact understanding of these when more shall have been collected. They are, probably, not nearly so rare as they seem; and further illustration may be gained from the study of other malformations of the ear in which the branchial fissure is concerned. Such are, probably, the rare cases of complete transverse bi-partition of the auricle; and a case described by Feist, in which there was a linear depression in the helix, anthelix, and tragus, a trace of which appeared in a line on the cheek and nose, while behind the auricle were four small blind pits.

If we bring together all the cases of branchial fistulæ now known, it appears that there are instances of defective closure of every one of the post-oral branchial fissures.

The aural fistulæ, such as I have described, are defects in the closure of part of the first fissure; that is, of that part of the fissure between the mandibular and hyoid arches which is not used in the formation of the external meatus, tympanum, and Eustachian tube.

The upper cervical fistulæ are defects in the closure of the second fissure; that, namely, which is between the hyoid and the thyro-hyoid arches.

The lower cervical fistulæ may be regarded as similar

<sup>1</sup> All the cases, except that by Lincke, are collected by Schmitz, *loc. cit.*

<sup>2</sup> Quoted by Lincke, *loc. cit.*

defects between the thyro-hyoid and the fourth or sub-hyoid arches, or between the lowest of these arches and the upper boundary of the chest.

In association with these malformations it is very interesting to observe some of the instances of what are called supernumerary auricles. The natural auricle may be regarded as a developed and utilised opercular skin-fold of the first post-oral branchial cleft; and growths of skin, more or less resembling auricles, have been found, however rarely, in the situations at which are found cervical branchial fistulæ, the remnants of the lower branchial clefts.

The best case is that by Mr. Birkett,<sup>1</sup> of a girl seven years old, in whom there were two supernumerary auricles, as of ears, on the sides of the neck, one over the middle of each sterno-mastoid muscle, that is, in the ordinary position of the upper cervical branchial fistulæ. Mr. Birkett's account leaves no room for doubt that they were rudimental external ears; "the tissues of the lobes and of the fibro-cartilage of the auricle were clearly distinguished."

Mr. Holmes<sup>2</sup> also gives a case, showing association of a supernumerary ear and a branchial fistula. In a little child "a small pendulous body, something like the supernumerary ears, was attached to the skin near the hyoid bone;" and there was "a small sinus, about three quarters of an inch above the sternum, and leading down towards but not to that bone."

In one of Heusinger's cases,<sup>3</sup> a flat, notched process of skin was attached just above the sterno-clavicular articulation, and at the inner edge of the sterno-mastoid muscle, and on raising it a well-marked branchial fistula appeared.

It thus seems probable, that in these malformations we may discern remnants of the serial homology, not only of the branchial fissures, but of their opercular skin-folds in the human subject. And similar facts are to be found in the less rare or even frequent occurrence of auricles, or

<sup>1</sup> 'Transactions of the Pathological Society,' vol. ix, p. 448, 1858.

<sup>2</sup> 'Surgical Treatment of Children's Diseases,' p. 140.

<sup>3</sup> Loc. cit., p. 359; and for a probable though less marked case, p. 363.



portions of skin-like auricles, on the necks of sheep, goats, and pigs.<sup>1</sup>

Dr. Allen Thomson<sup>2</sup> long ago pointed out a principle of great importance in the fact that malformations of the external ear are often associated with malformations of parts nearly connected with the first or mandibular branchial arch; for example, with hare-lip and cleft palate. And more recently, Virchow<sup>3</sup> has illustrated the same principle, especially in the frequent coincidence of such malformations with supernumerary auricles or "auricular appendages." I have not found any instances of other malformations associated with the aural branchial fistulæ; but there has been a remarkable frequency of deafness in various degrees in the persons in whom these fistulæ have been seen. My friend, in whom and in whose family the cases I have related have occurred, describes himself as "dull of hearing" on the right side; his father, who had cervical fistulæ, was very deaf in one ear; his sister, who has an aural fistula, uses a speaking trumpet; his eldest daughter, who has two aural fistulæ, has

<sup>1</sup> Wilde, 'Aural Surgery,' 1858, p. 158; and especially K. F. v. Heusinger in the 'Deutsche Zeitschrift,' loc. cit. I believe that such supernumerary auricles are not found on other parts than those connected with branchial fissures. The skin-growth often seen near the true auricles, or on the cheeks, are probably growths of the same opercular skin-fold as the auricle from which they look like bits detached. Or they are auricles displaced, but still in the line or region of the mandibular arch, as in a case by Fielitz ('Stark's Archiv für Geburtshülfe,' B. ii, St. 1, p. 71), and in several of those collected by Virchow, 'Archiv,' B. xxx, xxxii. The case quoted by Wilde, and then by Virchow, and others from Cassebohm, of two supernumerary auricles on the back of the neck, was that of a double-headed Cyclopiian monster, and these were the normal auricles appropriate to the two internal ears of the adjoining and partially fused sides of the heads (see Cassebohm, 'Tractatus sextus de Aure humana,' Halæ, 1734). And Wolff's case, often quoted from Voigtel ('Pathologische Anatomie,' 1804, p. 35), was that of a headless fœtus in which an ear on the left shoulder was matched by a mouth on the right. Lincke, loc. cit., quotes from Sebenicius, an instance of ears on the upper part of the neck, but he does not say on which aspect of the neck, and I have not been able to refer to the original paper.

<sup>2</sup> 'Edinburgh Monthly Journal of Med. Science,' vol. vii, 1846, p. 420.

<sup>3</sup> 'Archiv für Pathol. Anatomie,' B. xxx, and in a very remarkable case in B. xxxii, p. 518.

always been a little deaf, and more so in cold weather; and his youngest son, who has fistulæ in the neck but not in the ears, "has been decidedly deaf, but is now said to be improving." He adds, "I have a brother whose ears are most rudimentary. He is very deaf."

So in Heusinger's second case, the child with two aural fistulæ was brought to him for hardness of hearing, and was defective in discerning the direction of sounds. In Schmitz's first case, the father of the girl with aural fistulæ was completely deaf; her mother, sister, and aunt were very hard of hearing, and she herself had recently had otorrhœa and perforation of the left tympanum. In his second case the aural fistulæ were observed in a deaf old man.

It is hard to believe that so great frequency of defective hearing in the subjects of aural branchial fistulæ should be casual; and though, because the deafness was not congenital, we may hold that there was not, in these cases, any malformation of the interior structure of the ear, yet we may well believe that there was so much defect of texture as rendered some parts of the ear morbidly liable to disease. Allen Thomson and Virchow have shown how the disease of the embryo, whatever it may be, which hinders the development of the external ear, often causes other malformations by its extension over the mandibular branchial arch and the parts closely adjacent to it. Similarly, in these instances of diseases hindering the complete closure of the first or second branchial fissure, the morbid process seems to affect, in however slight a degree, the structures of the nearly related parts, and to render them, like all structures that have ever been diseased, specially liable to disease in later life.

---

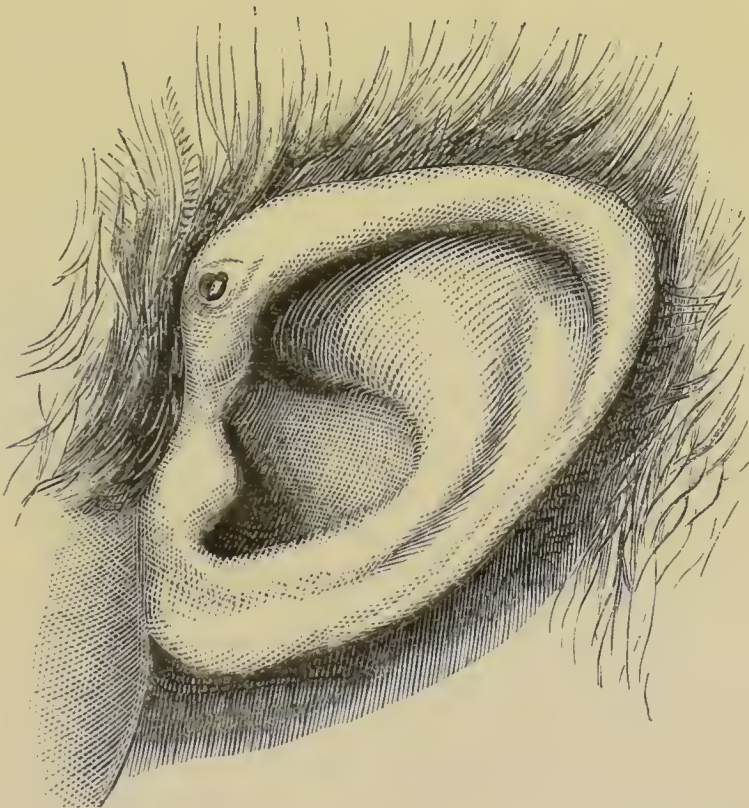
#### APPENDIX.

Since writing the foregoing paper I have received, through the kindness of Mr Cumberbatch, notes of a case which he has lately observed, and in which the traces of the branchial

fissure appeared on the helix, and by inheritance, but in the form of pits, not of canals.

Mr. C—, æt. 26, was deaf after scarlet fever in childhood. The right membrana tympani was thickened, dull white, and depressed anteriorly. The tip of the malleus-handle was somewhat enlarged. In the left ear similar appearances were more marked, and there were traces of an old perforation at the anterior lower segment of the membrana tympani. The tuning fork was heard distinctly when placed on the vertex of the head, and equally well on both sides.

The pinnae of the ears were peculiar in shape, being somewhat triangular, and on the upper part of each helix, close to the skin of the temple, there was a small depression large enough to admit a No. 4 shot. (See woodcut.)



The patient's maternal grandmother, and her eldest daughter had similar pits in similar situations on their ears. But no cases of harelip, cleft palate, or other deformity, had

been known in the family, and deafness was not prevalent among them.<sup>1</sup>

<sup>1</sup> Since the reading of the paper an essay on the subject has been published in the 'Edinburgh Medical Journal,' February, 1878, by Dr. Victor Urbantschitsch, "Concerning the so-called *Fistula Anris congenita*." In about 2000 aural cases he found twelve fistulæ. He refers to cases other than those which I have cited, and yet more references may be found in Jean Cusset's '*Étude sur l'Appareil Branchial des Vertébrés*,' 8vo, Paris, 1877. But the pathology of the branchial apparatus is overpassed when, in this essay, the cutaneous cysts found by the upper margin of the orbit and in the intermaxillary and other fissures are included among branchial cysts.

Through the kindness of Mr. Dalby and Mr. Mason I have seen two cases in which, with very imperfectly formed auricles and closed external meatus and small lower jaw, just as in one of Dr. Allen Thomson's cases, there was on each side a small shallow pit in front of the imperfect auricle. This pit or fistula might be likened to a branchial fistula, or else be regarded as an incomplete integumental portion of the imperfectly formed external meatus. Moreover, in Mr. Mason's case there was on each side, near what might be regarded as the upper edge of the incomplete helix, a smaller pit, about a line in depth, probably indicating a mere trace of a branchial fistula.